https://doi.org/10.17221/90/2026-CJAS

Survival and health status of *Pangasianodon hypophthalmus* treated with *Cosmos caudatus* and infected with *Aeromonas hydrophila*

Windarti Windarti[1]*, *Ronal Kurniawan*[2,4], *Irwan Effendi*[3,4], *Asmika Harnalin Simarmata*[1], *Efawani Efawani*[1]

[1]*Department of Aquatic Resources Management, Faculty of Fisheries and Marine, University of Riau, Indonesia*
[2]*Department of Aquaculture, Faculty of Fisheries and Marine, University of Riau, Indonesia*
[3]*Department of Marine Science, Faculty of Fisheries and Marine, University of Riau, Indonesia*
[4]*Center for Peatland and Disaster Studies, University of Riau, Indonesia*

**Corresponding author: windarti@lecturer.unri.ac.id*

Citation: Windarti W., Kurniawan R., Effendi I., Simarmata A.H., Efawani E. (2026): Survival and health status of *Pangasianodon hypophthalmus* treated with *Cosmos caudatus* and infected with *Aeromonas hydrophila*. Czech J. Anim. Sci., 71: 536–551.

Abstract: This study aimed to assess the efficiency of the high antioxidant content in *Cosmos caudatus* in improving the health of cultured *Pangasianodon hypophthalmus* infected with *Aeromonas hydrophila*. Treatments applied were PC (without *C. caudatus*, infected with *A. hydrophila*), NC (without *C. caudatus*, without infection), and 1 kg of feed mixed with 10 g (T1), 15 g (T2), and 20 g (T3) of *C. caudatus* powder. Furthermore, *P. hypophthalmus* fingerlings were reared in 100 l plastic tanks, 30 fish/unit, fed 3 times/day, at satiation. On day 61, the fish were intramuscularly injected with *A. hydrophila* (0.1 ml, 10^8 cells/ml) and reared for the next 14 days. The haematological condition of the fish was checked 3 times, while pre-treatment was conducted on days 60 and 75. The gill, liver, and kidney were taken for histological study on day 75. Clinical signs and survival were monitored on a daily basis. The results showed that the PC fish developed severe ulcers, with the lowest survival percentage of 40.00 ± 3.00 (PC), 89.67 ± 5.77 (NC), 92.00 ± 1.73 (T1), 86.67 ± 3.51 (T2), and 83.33 ± 3.51 (T3) on day 14. *C. caudatus*-treated fish reported better performance, and the wound started curing on day 5 post-infection. Most fish were fully recovered on day 14, and the tissues of PC showed severe abnormalities such as necrosis, haemorrhage, and damaged cells. On days 60 and 75, the *C. caudatus*-treated fish reported higher total erythrocyte and haemoglobin content and phagocytic index (27.00 ± 1.00% in T1). The PC fish had the worst haematological condition with the lowest total leucocyte (1.33 ± 0.57) and phagocytic index (9.33 ± 1.15).

Keywords: infection sign; motile *Aeromonas* septicaemia; tissue abnormality; ulam raja; ulcer

Supported by the Universitas Riau through the "Riset Unggulan Universitas Riau DIPA UNRI 2025" research grant (29103/UN19.5.1.3/AL.04/2025).

© The authors. This work is licensed under a Creative Commons Attribution 4.0 International (CC-BY 4.0) license.

https://doi.org/10.17221/90/2026-CJAS

Fish culture has been developing over the last decade in Riau province, Indonesia. Freshwater fish culture was mainly applied in areas with potential aquatic resources, such as lakes, dams, or rivers. Floating net cages are placed in a dam, river, or earthen pond to rear fish. Koto Masjid Village in the Kampar Regency is known as "Patin Village" because most residents cultivate *Pangasianodon hypophthalmus* as the primary source of income. In 2025, *P. hypophthalmus* production reached 300 tonnes/month (DKP Kampar 2025). The fish produced are sold as fresh and smoked fish, as well as other products such as floss and crackers.

A common problem in the culture of *P. hypophthalmus* is the attack by pathogens, including *Aeromonas hydrophila*, which causes MAS (motile *Aeromonas* septicaemia) disease. The risk of *A. hydrophila* infection increases when fish are reared in high stocking densities with inadequate culture management and poor water circulation. This condition causes stress in fish and increases the likelihood of infectious diseases spreading in culture areas (Hasan and Haque 2020). In fish culture, outbreaks of MAS may be difficult to stop since the disease spreads quickly through water flow or contaminated agents. The disease caused by *A. hydrophila* leads to high mortality rates and economic losses in aquaculture (Elsheshtawy et al. 2019; Abdella et al. 2024; Jiang et al. 2025), with 80% loss in a 1–2 week period (Korni et al. 2017; Algammal et al. 2020). The performance of fish attacked by *A. hydrophila* was poor, and the economic value of the fish may be reduced due to haemorrhagic skin ulcers, cataracts in the eyes, tail and fin damage, as well as gill haemorrhage (Soliman et al. 2022). Yousefi et al. (2021) reported that fish suffering from MAS disease exhibited tissue and organ damage, growth arrest, and mass mortality.

Antibiotics such as doxycycline, flumequine, and oxytetracycline are used to treat the bacterial infection (Soliman et al. 2022). However, the use of antibiotics in cultured fish has negative impacts since the consumption may not be properly discharged (Nguafack et al. 2020). This can promote the development of new strains of antibiotic-resistant bacteria, which can cause another outbreak in the future (Thornber et al. 2020). The use of antibiotics derived from natural sources to address bacterial attack-related problems might be preferable since the treatment does not leave any residue in the meat or promote the development of antibiotic-resistant bacteria. Another approach to reducing the risk of bacterial infections is to improve fish immunity and overall health using natural sources.

Cosmos caudatus is well known as *kenikir* or *ulam raja*, and can be commonly used as a vegetable. This herb improves the immunity or the general health of the fish, which contains alkaloids, flavonoids, saponins, phenolic acids, vitamin C, quercetin, beta-carotene, and kaempferol, acting as immunostimulants (Jana et al. 2018). Chemicals present in *C. caudatus* act as antimicrobials and antioxidants, and may improve fish immunity and growth. Fish immunity and health are represented by the ability to withstand *A. hydrophila* attack, as reflected in survival and clinical signs after infection with *A. hydrophila*. The immunity condition can be monitored through the haematological condition of the fish, especially the phagocytic index that represents the ability of fish to face pathogen attack.

In *P. hypophthalmus* reared in saline media, the provision of *C. caudatus*-mixed pellets improved growth and survival (Simarmata et al. 2025). However, there is no information on the efficiency of *C. caudatus* in reducing the negative impact of *A. hydrophila* infection, such as clinical signs, haematological condition, and tissue structure. This study was conducted to assess the effectiveness of *C. caudatus* in mitigating the negative effects of *A. hydrophila* infection in *P. hypophthalmus*. The fish are more resistant, reducing the fatal impact of the pathogen and promoting the recovery, growth, and survival of the fish by being fed pellets enriched with *C. caudatus*.

MATERIAL AND METHODS

This study was conducted from April to August 2025 and was located at the Laboratory of Marine Microbiology, the Faculty of Fisheries and Marine Science, Universitas Riau, Pekanbaru, Indonesia. An experimental method using a one-factor Completely Randomised Design (CRD) with five treatments and three-unit replications (30 fishes/unit) was applied, and 15 experimental units were required. *C. caudatus* dosages applied were in line with previous studies (Simarmata et al. 2025), as follows:

- NC = negative control (no *C. caudatus* and no *A. hydrophila* infection);

https://doi.org/10.17221/90/2026-CJAS

- PC = positive control (no *C. caudatus* and was infected with *A. hydrophila*);
- T1 = *C. caudatus* powder addition (10 g/kg feed) and was infected with *A. hydrophila*;
- T2 = *C. caudatus* powder addition (15 g/kg feed) and was infected with *A. hydrophila*;
- T3 = *C. caudatus* powder addition (20 g/kg feed) and was infected with *A. hydrophila*.

The *C. caudatus* powder was coated onto the fish feed pellets to prepare the *C. caudatus*-mixed pellets. *C. caudatus* obtained from the Pekanbaru local market was rinsed, sun-dried, blended, and sieved. The commercial pellets were coated with the powder as reported in previous study (Simarmata et al. 2025), where *i*) 20 g of tapioca powder was diluted in 50 ml of plain water at room temperature, *ii*) 100 ml of hot boiling water was poured into the tapioca mixture and stirred well to form a whitish, thick, sticky solution, *iii*) the necessary dosages of *C. caudatus* were added and mixed well, and *iv*) 1 kg of fish feed pellets was added with *C. caudatus* mixture, mixed manually, and sun-dried. These pellets can be stored in closed plastic bags or containers and are ready for feeding the fish.

Fingerlings of *P. hypophthalmus* (5.00 ± 1.00 g b.w. and 50.00 ± 10.00 mm total length) were used in this study. The fish were reared in a 100 l circular plastic tank (60 cm diameter) filled with 100 l of freshwater with a density of 30 fishes/tank. An aquaponic system with *Ipomoea aquatica* was set up (20 plants/unit) in each tank to maintain the water quality. A circulatory pump (800 l/hour capacity) was installed at the base of each tank to pump the water containing aquaculture waste to the aquaponic units. The plant roots absorbed organic materials as water flowed into the aquaponic unit, and the cleaned water moved to the rearing tank.

In the 1st–3rd week, the fish were fed on F999 fish feed pellets by PT CPP (Central Proteina Prima). The feed was replaced with the larger granule pellet (F 781-1) as fish grew and the mouths widened. During the study, the fish were fed in the morning, noon, and evening (3 times/day) at satiation. The feed was provided in steps, with only a few pellets given at each step. More pellets were given after the fish finished the previous feed and showed an interesting response. Feed provision stopped when the fish lost interest in feeding.

After the provision of *C. caudatus*-mixed pellets for a period of 60 days, the fish were infected with *A. hydrophila* (intramuscular injection, 0.1 ml, 10^8 cells/ml). *A. hydrophila* used was obtained from the bacteria collection of the Integrated Laboratory, Fisheries and Marine Science Faculty of University of Riau, Indonesia. Koch's postulates were applied to increase the virulence of the bacteria before being used for the challenge test. The infected fish were reared and fed *C. caudatus*-mixed pellets for 14 days. Fish survival was monitored at least 2 times/day, but the feed remained, and dead fish were removed. During the first 60 days, the growth was monitored every 10 days. In each sampling, 15 fish per tank were measured and weighed. Fish growth was monitored on day 14 post-infection or at the end of the experiment. During the 14 days, the *C. caudatus* mixed pellets were continuously given to the fish. In each tank, 15 fish were taken randomly as a subsample. The fish's total length and body weight were measured using a ruler and a digital scale. Data at the level of the experimental unit (tank) or the average length and weight data of 15 fish from a single experimental unit were analysed using a one-way ANOVA. After infection with *A. hydrophila*, the clinical symptoms were investigated daily. The clinical sign parameters were fish behaviour, fish appetite, growth (before and after infection), the presence of haemorrhagic ulcers, exophthalmia, and fin/tail damage. The fish used in the experiment were treated in accordance with the animal ethics guidelines provided by Syiah Kuala University (Hasanuddin 2015).

The formula used to calculate the absolute growth is as follows:

$$AGR = W_2 - W_1 \quad (1)$$

where:
AGR – absolute growth (g);
W_2 – the average body weight of the treated fish on the last day of the experiment (g);
W_1 – the average body weight of the treated fish on the initial day (g).

The formula used to calculate the specific growth rate is as follows:

$$SGR = \frac{\ln W_t - \ln W_1}{t} \times 100\% \quad (2)$$

where:
SGR – specific growth rate (%/day);
W_1 – the average of the treated fish body weight on the

https://doi.org/10.17221/90/2026-CJAS

initial day of the experiment (g);
W_t – average final fish weight (g);
t – duration of the experiment (days).

The food conversion rate (FCR) and food efficiency (FE) were calculated to monitor the feed used during the experiment. The FCR on days 60 and 75 was calculated. During the experiment, the fish were fed ad satiation. The quantity of feed eaten by the fish was checked by providing a small container containing 100 g of feed pellets. Approximately 100 g of pellets were added when the feed was finished, or within a week. The fish feed pellets left in the bottle were weighed weekly, and additional pellets were weighed. The total amount of fish pellets consumed by the fish was reported on the last day of the experiment. These data were used to calculate the FE and FCR. The formula used to calculate the FE is as follows:

$$\text{FE} = \frac{(W_t + D) - W_o}{F} \times 100\% \quad (3)$$

where:
FE – food efficiency (%);
F – the weight of food that was eaten by the fish during the experiment (g);
D – the weight of fish that died during the experiment (g);
W_t – average final fish weight (g);
W_o – the fish's total weight on the initial day (g).

The formula used to calculate the food conversion rate (FCR) is as follows:

$$\text{FCR} = \frac{F}{(W_t + D) - W_o} \quad (4)$$

where:
FCR – food conversion rate;
F – the weight of food that was eaten by the fish during the experiment (g);
D – the weight of fish that died during the experiment (g);
W_t – average final fish weight (g);
W_o – the fish's total weight on the initial day (g).

The water in the rearing media was maintained by removing uneaten feed remains. The volume was maintained by adding a small amount of water every day due to evaporation. Around 25% of the rearing water was taken and replaced with an equivalent volume of clean freshwater once a week to maintain the water quality. On day 75 (14 days post-infection), 15 fish from each treatment were sacrificed, and the gill, kidney, and liver tissue were taken and processed for histological analysis. The fixative used was 10% formalin, and the tissue samples were immersed in the solution for 48 hours. The solution was replaced with 4% formalin and kept for a minimum of three days. For histological analysis, the samples were processed through a routine technique, especially dehydration (in an alcohol series), and continued with the impregnation and embedding process in paraffin. To prepare the sample, 5–7 micrometre sections were made using a manual rotary microtome. The tissue sections were stained using haematoxylin-eosin and mounted with DPX. The specimens were investigated using a binocular microscope, Olympus CX-21 series. Meanwhile, the photographs were taken using a Hirox digital microscope RX-100 before reporting abnormalities in the tissue.

The histopathologic alterations of the tissue were scored from 0 to 3 following Flores-Lopes and Thomaz (2011) for gill tissue, where 0 = the tissue is normal, and there is no abnormality (alteration), 1 = the alteration is slight or minor, 2 = the alteration is moderate, and 3 = the alteration is severe. The stages of gill abnormality were adapted from Poleksic and Mitrovic-Tutundzic (1994). Minor or slight alteration (I) shows that the abnormality does not destroy the gill tissues, and restructuring or recovery of gill function occurs with improved environmental conditions. Moderate alteration (II) reports more severe changes affecting tissues and the function of the organ. These abnormalities, including epithelial lifting of secondary lamellae, are reparable lesions, but the presence of the lesion in relatively wide areas of the gills may lead to severe alterations. The severe alterations, such as aneurysms (III), indicate that the gill has been damaged. Table 1 shows that there is no recovery in the gill structure, even though the water quality has improved.

Histopathologic alterations of fish gills were determined using a semi-quantitative index based on the degree or severity of the tissue lesion (histopathologic alterations index or HAI) adapted from Poleksic and Mitrovic-Tutundzic (1994). Each organ's abnormality was categorised into "progressive stages of damage in the tissues". This index value of each fish was analysed by the formula: HAI = $(1 \times S_I) + (10 \times S_{II}) + (100 \times S_{III})$. The symbols I, II, and

https://doi.org/10.17221/90/2026-CJAS

Table 1. Types of structure alterations present in the gills (modified from Poleksic and Mitrovic-Tutundzic 1994)

Stages	Scores	Tissue structure alterations in the fish gills
I	1	The epithelium of the gill shows cell hypertrophy and hyperplasia, sanguineous blood congestion, enlargement of the peripheral vascular channels, raising of the respiratory epithelium, fusion and disorganisation of the secondary lamellae, secondary lamellae shortened or curled, penetration of leucocyte cells to the gill epithelium.
II	10	Haemorrhage and broken lamellar epithelium, the mucous cells show hypertrophy and hyperplasia, mucous cells disappear or are empty, chloride cells show hypertrophy and hyperplasia.
III	100	The secondary lamellae show telangiectasis or aneurysm, necrosis, and cell degeneration in the gill, telangiectasis in the secondary lamellae.

III represent the number of stages of abnormality. Meanwhile, I, II, and III, as well as *S*, symbolise the sum of the numbers for each specific stage. The values of HAI between 0–10, 11–20, 21–50, 51–100, and more than 100 show that the tissue has normal, minor, moderate, acute, and irreparable damage, respectively.

Haematological parameters and phagocytic index. Fish blood was sampled three times during the experiment on days 0 (before treatment with *C. caudatus*), 60 (after feeding with *C. caudatus*-enriched pellets before being infected with *A. hydrophila*), and 75 (on day 14 post-infection). Sedation was conducted using clove oil (5 drops/l), and blood was collected from the caudal vein using a sterile 1 ml syringe wet with 10% EDTA solution. The blood was transferred into 1.5 ml Eppendorf vials moistened with EDTA and kept on crushed ice in a filled cool box. Total erythrocyte and leucocyte counts were conducted using a Neubauer haemocytometer. Haematocrit and leucocrit were determined using heparinised capillaries centrifuged at 12 000 rpm for 3 min, and a Sahli haemoglobinometer was used to measure the haemoglobin concentration. The differential leucocyte count (lymphocyte, monocyte, neutrophil, and thrombocyte) was conducted from blood smear samples. The blood smears were fixed using 96% methanol and stained with 50% Wright-Giemsa solution. Approximately 100 leucocyte cells per smear were examined and classified using a light microscope (Olympus CX 21) at 1 000× magnification using immersion oil.

A method modified from Siwicki et al. (1993) was applied to understand the Phagocytic Index. The red blood cells in the centrifuged micro-haematocrit capillaries were removed by cutting the capillaries below the leucocyte section. Leucocytes and serum were placed in 1.5 ml Eppendorf tubes, with 50 µl of *Staphylococcus aureus* culture (10^8 cells/ml), and the mixture was incubated for 30 minutes. Smears of the mixture were fixed and stained with Wright-Giemsa solution and were counterstained with 50% Carbol Fuchsin for 3 min to visualise the bacteria. The percentage of leucocytes showing phagocytic activity was determined from 100 leucocytes identified under the microscope.

Water quality measurement. Water quality was measured once every 10 days, and the parameters measured were water temperature, pH, dissolved oxygen (DO), and ammonia content. Water temperature, pH, and DO were measured using a multi-parameter water quality meter, namely AZ 8685 and AZ 8403, respectively. Ammonia concentration was measured using a spectrophotometer, Biobase BK-UV1800.

Data analysis. Data on growth parameters, survival, FE, and FCR were tabulated and analysed using SPSS v24 (IBM, USA). A one-way ANOVA was used to identify differences among treatments, followed by a Student–Newman–Keuls post-hoc test to determine the specific group means. The histology data of the gill, kidney, and liver of the fish were described. Data on the haematological parameters and phagocytic index were analysed using the same statistical procedures.

RESULTS

Clinical signs. During the experiment, clinical signs of the treated fish were monitored daily during a 14-day period post-infection with *A. hydrophila*, from days 61 to 75 at the end of the experiment. The clinical sign parameters monitored were behaviour, food intake, wound at the injection site, haemorrhagic wounds present, and damage to fins and tail. The clinical signs of the fish were presented in Table 2.

https://doi.org/10.17221/90/2026-CJAS

Table 2. Clinical signs of *P. hypophthalmus* fed with *C. caudatus* and infected with *A. hydrophila*

No.	Day	PC	NC	T1	T2	T3
1	day 1 to day 60 (*C. caudatus* treatment)	eating well; growing well	eating well; growing well	eating well; growing well, better weight	eating well; growing well, better weight	eating well; growing well, better weight
2	day 1 post-infection	no special clinical signs, loss of appetite	no infection, no special clinical signs	no special clinical signs, loss of appetite	no special clinical signs, loss of appetite	no special clinical signs, loss of appetite
3	day 4 post-infection	the wound is getting bigger, red, and more inflamed, and several fish die, do not eat	no special signs	in some fish, the wound became bigger, red, and inflamed. a few fish die, but other fish are getting better and start to eat the feed provided	in some fish, the wound gets bigger, red, and inflamed. few fish die, but other fish are getting better and start to eat the feed provided	in some fish, the wound is getting bigger, red, and inflamed. few fish die, but other fish are getting better and start to eat the feed provided
4	day 8 post-infection	the wound worsened, became weak, did not eat, and more fish died	no special signs	in general, the wound starts to heal, more active in moving and feeding	in general, the wound starts to heal, more active in moving and feeding	in general, the wound starts to heal, more active in moving and feeding
5	day 14 post-infection	most fish die; the rest that are alive show signs of recovery: the wounds start to heal, the fish move and eat actively	no special signs	the wound healed, covered with thin whitish skin, the fish is active, moving and feeding.	the wound recovered, covered with thin, whitish skin, the fish is active, moving, and feeding.	the wound recovered, covered with thin, whitish skin, the fish is active, moving, and feeding.

NC = negative control; PC = positive control; T1 = *C. caudatus* powder addition (10 g/kg feed); T2 = *C. caudatus* powder addition (15 g/kg feed); T3 = *C. caudatus* powder addition (20 g/kg feed)

During the period from the 1st to the 60th day, no difference in the feeding behaviour was observed in the control and the treated fish. All fish responded positively to the food provided, showing that the supplementation of *C. caudatus* did not cause a negative effect on appetite. The fish grew well, and the mortality rate was low during the *C. caudatus* treatment. In each tank (30 fishes/tank), only 1–3 fish died between days 1 to 10, and no deaths were recorded between days 11 to 60. Fish mortality during the first 10 days may have been associated with stress caused by transferring the fish from a large fibreglass tank to smaller treatment tanks. The absence of mortality from day 11 to 60 suggested that *C. caudatus* treatment did not cause detectable lethal effects. The fish may have experienced improvements in immune function, but further evidence is required to confirm the possibility.

On day 61, immediately after injection with *A. hydrophila*, the fish exhibited similar stress responses, including loss of appetite and reduced activity, without specific clinical signs. Clinical manifestations of *A. hydrophila* infection became apparent on day 2. All infected fish developed redness at the injection site, followed by ulcer formation, which worsened by day 4, when several fish died. Some surviving fish treated with *C. caudatus* showed signs of recovery and resumed feeding. The positive control group reported progressive disease, characterised by enlarging ulcers, the appearance of additional haemorrhagic ulcers, increasing fin and tail damage, and rising mortality. On day 8, mortality had increased in the positive control group, while the *C. caudatus*-treated fish showed visible improvement, with smaller wounds covered by a thin, whitish layer.

https://doi.org/10.17221/90/2026-CJAS

The *C. caudatus*-treated fish had fully recovered on day 14, as reported by wound healing, increased swimming activity, and the resumption of feeding. Surviving fish in the positive control group also showed signs of recovery and resumed feeding. Exophthalmia was not observed in any fish during the experiment. The negative control group exhibited no specific clinical signs, consistent with the absence of *C. caudatus* treatment and *A. hydrophila* infection.

Growth rate of *P. hypophthalmus*. Body length, weight, specific growth rate, and biomass were measured every 10 days to monitor the growth of the fish during the experiment. The first part of this study was the period during *C. caudatus*-enriched pellet feeding from days 1 to 60 of the experiment. The second part was the period after the fish were injected with *A. hydrophila* culture, from days 61 to 75. There was no variation in the total body length of the fish across all treatments, but there was a difference in total weight. The fish fed with *C. caudatus* were significantly heavier than those in positive and negative controls. Among the fishes fed with *C. caudatus*, T1 (fed with 10 g *C. caudatus* powder/1 kg of pellets) was the heaviest.

The data obtained showed that fish in all treatment groups performed well up to day 60. After infection with *A. hydrophila*, growth patterns varied depending on the treatment applied (Figure 1). In addition to growth, the biomass of the fish increased from day 1 to day 60, but it did not increase or decrease after *A. hydrophila* infection. In the positive control fish (PC), biomass decreased sharply, with many fish dying and only 40% surviving on day 75 (Table 3).

Histological study. Improved performance was reflected in the tissue structure of fish fed pellets supplemented with *C. caudatus*. Histological study of the organs removed on day 14 post-infection suggested that the condition of gill, liver, and kidney tissues was poor in the positive control fish (no *C. caudatus* and infected with *A. hydrophila*). Several abnormal signs such as hypertrophy and hyperplasia in the gills, necrosis, haemorrhage, and damaged cells in the tissue were present. The organ structure of the negative control and the *C. caudatus*-treated fish showed slight abnormalities. There was no significant distinction in the structure of the organs of *C. caudatus*-treated fish (Table 4).

On the 14th day after being infected with *A. hydrophila*, the gill, kidney, and liver tissue structure of the fish fed with *C. caudatus*-enriched pellets and the positive control (PC) showed significant differences. The organs of the PC fish were badly damaged and showed characteristics of *A. hydrophila* infection. In contrast, the organs of fish fed with *C. caudatus*-mixed pellets showed light abnormalities (Figure 2).

The condition of the tissue structure of fish fed with different dosages of *C. caudatus* (T1, T2, and T3) showed no difference. Only a few cells showed light abnormalities such as hyperplasia, hypertrophy, epithelium lifting, and curling lamellae. These abnormalities were not permanent and were cured with improved environmental conditions. The condition of the PC gill structure was poor, and many

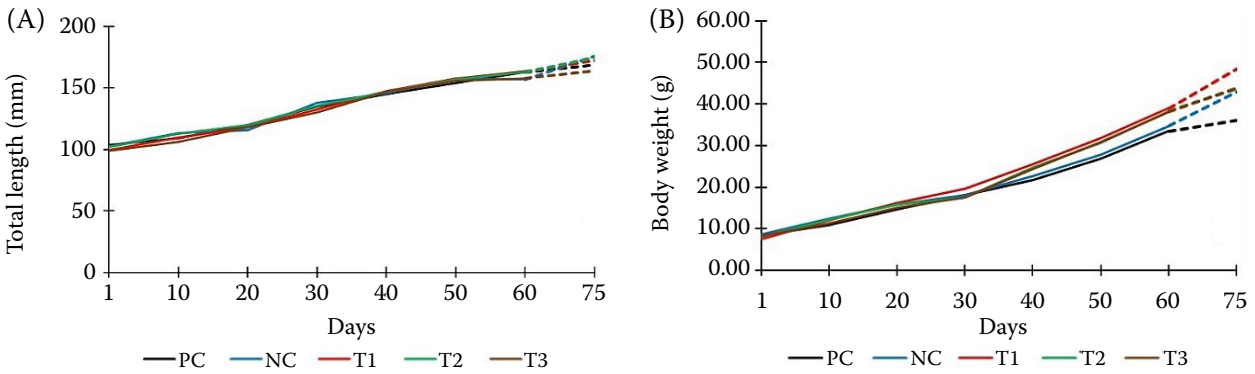

Figure 1. Growth of *P. hypophthalmus* fed with *C. caudatus*-enriched pellets and infected with *A. hydrophila,* length growth (A) and weight growth (B). Solid lines represent the growth of fish before infection, while the broken line indicates the growth of fish after being infected with *A. hydrophila*

NC = negative control; PC = positive control; T1 = *C. caudatus* powder addition (10 g/kg feed); T2 = *C. caudatus* powder addition (15 g/kg feed); T3 = *C. caudatus* powder addition (20 g/kg feed)

https://doi.org/10.17221/90/2026-CJAS

Table 3. Growth and survival of *P. hypophthalmus* that was treated with *C. caudatus*-mixed pellets and infected with *A. hydrophila*

Parameters	Treatments				
	PC	NC	T1	T2	T3
Day 60					
Total length (mm)	58.9 ± 5.60	54.1 ± 4.10	64.0 ± 7.00	61.0 ± 4.70	58.7 ± 1.04
Total weight (g)	24.92 ± 0.82^{a}	26.08 ± 0.08^{b}	31.39 ± 0.17^{d}	30.30 ± 0.34^{c}	29.87 ± 0.81^{c}
Specific growth rate (%/day)	2.28 ± 0.13^{a}	2.33 ± 0.10^{a}	2.73 ± 0.05^{b}	2.62 ± 0.06^{b}	2.55 ± 0.03^{b}
Survival (%)	92.22 ± 1.92	91.11 ± 3.85	96.67 ± 3.33	96.67 ± 3.33	94.44 ± 1.92
Day 75					
Total length (mm)	64.77 ± 2.30	73.3 ± 1.20	72.8 ± 9.60	73.1 ± 5.30	65.1 ± 1.30
Total weight (g)	27.59 ± 0.67^{a}	34.28 ± 0.99^{b}	40.87 ± 1.22^{c}	35.69 ± 0.65^{b}	35.49 ± 0.84^{b}
Specific growth rate (%/day)	2.41 ± 0.12^{a}	2.68 ± 0.08^{b}	3.09 ± 0.07^{c}	2.83 ± 0.11^{b}	2.78 ± 0.09^{b}
Survival (%)	40.00 ± 3.00^{a}	89.67 ± 5.77^{b}	92.00 ± 1.73^{b}	86.67 ± 3.51^{b}	83.33 ± 3.51^{b}

$^{a–d}$Different superscripts indicate significant differences ($P < 0.05$); values are means ± SD

NC = negative control; PC = positive control; T1 = *C. caudatus* powder addition (10 g/kg feed); T2 = *C. caudatus* powder addition (15 g/kg feed); T3 = *C. caudatus* powder addition (20 g/kg feed)

Table 4. Tissue structure alterations in *P. hypophthalmus* treated with *C. caudatus* enriched pellets on day 14 post infection with *A. hydrophila*

No.	Organs	Alterations	Treatments				
			PC	NC	T1	T2	T3
1	gill	hyperplasia	√√√	√	√	√	√
		hypertrophy	√√√	√	√	√	√
		fused lamellae	√√√	√	√	√	√
		blood congestion	√	–	–	–	–
		haemorrhage	√√	–	–	–	–
		epithelial lifting	√	√	√	√	√
		short/curling lamellae	√	√	√	√	√
		necrosis	√√	–	–	–	–
		telangiectasis/aneurism	√	–	–	–	–
		HAI value	104.0	1.8	2.9	14.7	18.0
2	kidney	haemorrhage	√√√	–	√	√	√
		melanomacrophage	√	–	–	–	–
		damage Bowman capsule cells	√√√	–	–	–	–
3	liver	hepatocyte cell damage	√√√	–	–	–	√
		haemorrhage	√√√	–	–	–	–
		necrosis	√√	–	–	–	–

Explanation of the presence of cells with abnormalities: √ = few; √√ = several; √√√ = many; – = not detected

HAI = histopathologic alterations index; NC = negative control; PC = positive control; T1 = *C. caudatus* powder addition (10 g/kg feed); T2 = *C. caudatus* powder addition (15 g/kg feed); T3 = *C. caudatus* powder addition (20 g/kg feed)

cells showed non-reparable abnormalities such as necrosis and telangiectasis. The HAI values of NC, T1, T2, and T3 fish ranged from 1.8–18.0, indicating that the general condition of the gill was good and the abnormalities were reparable. In contrast, the gill of the PC fish was poor, and the HAI value was 104, indicating that the alteration was severe.

https://doi.org/10.17221/90/2026-CJAS

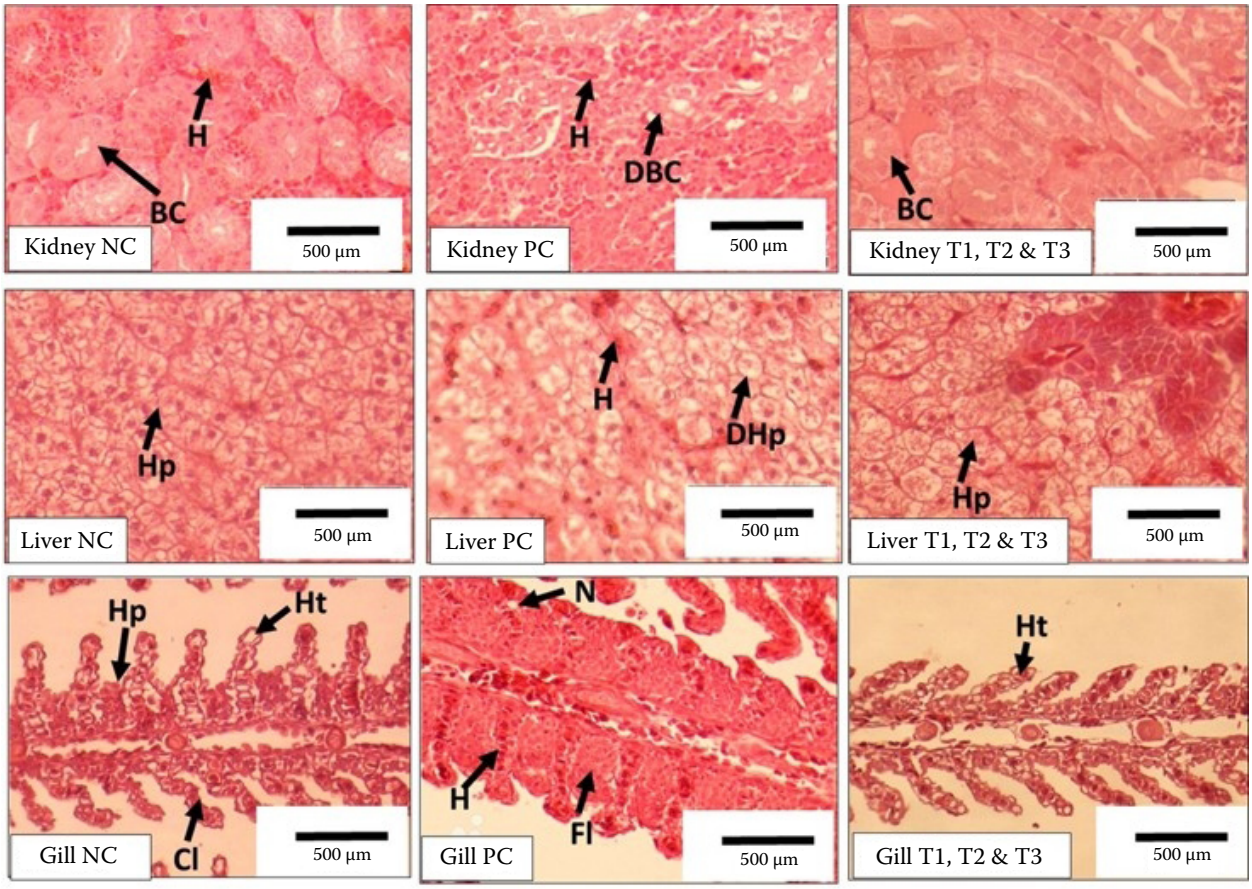

Figure 2. The structure of the gill, kidney, and liver of *P. hypophthalmus* fed on *C. caudatus* mixed pellets
BC = Bowman's capsule; Cl = curling lamellae; DBC = damaged Bowman's capsule; DHp = damaged hepatocyte cells; Fl = fused lamellae; H = haemorrhage; Hp = hepatocyte cells; HP = hyperplasia; Ht = hypertrophy; N = necrosis; NC = negative control; PC = positive control; T1 = *C. caudatus* powder addition (10 g/kg feed); T2 = *C. caudatus* powder addition (15 g/kg feed); T3 = *C. caudatus* powder addition (20 g/kg feed)

The liver, gills, and kidney of the PC fish were poor, while those of the NC, T1, T2, and T3 were good. In the kidney, there was heavy haemorrhage and damage in the Bowman's capsule cells and the liver.

Survival of *P. hypophthalmus*. On the last day of the experiment, survival of the control and treated fish differed. Many fish in the positive control treatment (no *C. caudatus*, infected with *A. hydrophila*) died, and only 40% survived. The negative control fish did not exhibit any specific symptoms because they were fed a diet without *C. caudatus* and were not infected with *A. hydrophila*. The *C. caudatus*-treated fish showed a higher survival rate, with 83–92% recovering from diseases caused by *A. hydrophila* (Figure 3).

The application of *C. caudatus*-enriched pellets to feed the fish improved the FCR and FE before and after infection with *A. hydrophila* (Table 5). The FCR and FE of the positive and negative control fish were significantly lower than those of the *C. caudatus*-treated fish. The control fish had approximately 55% FE and 1.83 FCR. The FE of the treated fish ranged from 67.60% to 73.12%, while FCR ranged from 1.37 to 1.48.

After infection with *A. hydrophila*, the FE and FCR of fish in all treatments were reduced. However, the values for the *C. caudatus*-treated fish were better than those in the positive control. The FE and FCR of the positive control fishes were 20.75% and 4.84, while the negative control and treated fishes were not significantly different. The values ranged from 49.72–58.67% in FE and 1.71–2.02 in FCR. Among the treated fish, T1 showed the best performance.

Haematological parameters and phagocytic index. Results of haematological profile and phagocytic index of *P. hypophthalmus* fed with *C. caudatus*-enriched pellets are presented

https://doi.org/10.17221/90/2026-CJAS

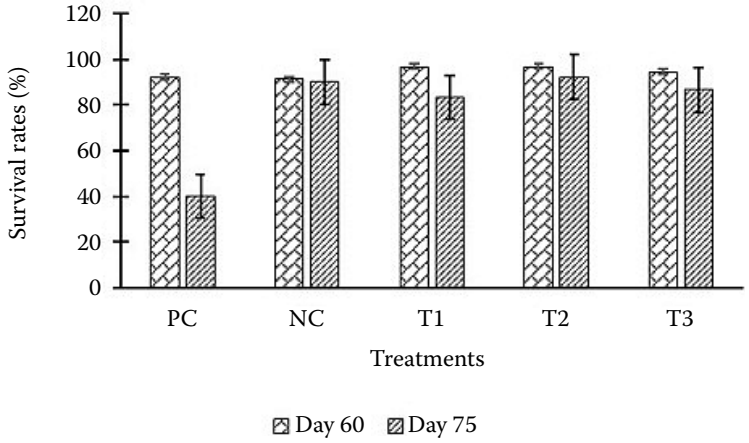

Figure 3. Survival of *P. hypophthalmus* fed with *C. caudatus*-mixed pellet and infected with *A. hydrophila* on days 60 and 75

NC = negative control; PC = positive control; T1 = *C. caudatus* powder addition (10 g/kg feed); T2 = *C. caudatus* powder addition (15 g/kg feed); T3 = *C. caudatus* powder addition (20 g/kg feed)

Table 5. Food conversion rate and food efficiency of *P. hypophthalmus* treated with *C. caudatus*-mixed pellets before and after *A. hydrophila* infection

Parameters	Treatments				
	PC	NC	T1	T2	T3
Day 60					
Food efficiency (%)	54.66 ± 0.58^{a}	55.63 ± 2.01^{a}	73.12 ± 0.73^{c}	68.37 ± 1.09^{b}	67.60 ± 0.41^{b}
FCR	1.83 ± 0.02^{c}	1.83 ± 0.01^{c}	1.37 ± 0.02^{a}	1.46 ± 0.03^{b}	1.48 ± 0.01^{b}
Day 75					
Food efficiency (%)	20.75 ± 1.81^{a}	49.72 ± 2.65^{b}	58.67 ± 3.26^{c}	51.70 ± 0.87^{b}	50.99 ± 2.56^{b}
FCR	4.84 ± 0.41^{b}	2.02 ± 0.10^{a}	1.71 ± 0.09^{a}	1.93 ± 0.03^{a}	1.96 ± 0.01^{a}

$^{a–c}$Different superscripts indicate significant differences ($P < 0.05$); values are means ± SD

On day 60: before the fish were infected with *A. hydrophila*; On day 75: 14 days after infection with *A. hydrophila*

FCR = food conversion rate; NC = negative control; PC = positive control; T1 = *C. caudatus* powder addition (10 g/kg feed); T2 = *C. caudatus* powder addition (15 g/kg feed); T3 = *C. caudatus* powder addition (20 g/kg feed)

in Table 6. On day 60, before being infected with *A. hydrophila*, fish treated with *C. caudatus* (T1, T2 and T3) showed significantly higher total erythrocyte and haemoglobin content than the control. Total leucocytes increased, with the highest recorded in T1, followed by T2 and T3, while the lowest values were in NC and PC. Lymphocyte percentage and phagocytic index were significantly higher in T1 only.

On day 14 after being infected with *A. hydrophila* (day 75), the positive control (PC) fish showed a clear decline in total erythrocyte, haemoglobin, haematocrit levels, lymphocyte, and phagocytic index. Monocyte, neutrophil, and thrombocyte percentages decreased, consistent with anaemia and stress-related leucocyte redistribution. Fish fed with *C. caudatus*-enriched pellets showed higher total erythrocyte and haemoglobin levels with further increase in phagocytic index. The highest phagocytic index was in T1, which was 27.00 ± 1.00%.

Water quality. In all experimental units, the water quality condition throughout the experiment was consistent with the threshold limit issued by the Indonesian government (Table 7). The water temperature was 26–30 °C, around 3 °C different from the ambient temperature in Pekanbaru at 23–34 °C. The pH of the water in rearing tanks fluctuated slightly, ranging from 6.2 to 6.9. The DO content ranged from 3.7 ppm to 5.6 ppm and

https://doi.org/10.17221/90/2026-CJAS

Table 6. Haematological parameters and phagocytic index of *P. hypophthalmus* fed with *C. caudatus* enriched pellets and infected with *A. hydrophila*

Parameters	Day 0	Treatments (*C. caudatus* dosages)				
		PC	NC	T1 (10 g/kg)	T2 (15 g/kg)	T3 (20 g/kg)
Day 60 (post-treatment with *C. caudatus*)						
Total erythrocyte (×10^6 cells/mm^3)	1.12 ± 0.02^a	1.65 ± 0.03^a	1.46 ± 0.03^a	1.90 ± 0.02^b	1.83 ± 0.01^b	1.79 ± 0.01^b
Haemoglobin (g/dl)	6.13 ± 0.11^a	6.53 ± 0.30^a	6.67 ± 0.23^a	7.53 ± 0.11^b	7.33 ± 0.11^b	7.20 ± 0.20^b
Haematocrit (%)	25.33 ± 0.57^a	32.00 ± 2.00^a	30.33 ± 1.52^a	36.00 ± 1.00^b	33.00 ± 1.00^a	31.66 ± 0.57^a
Total leucocyte (×10^4 cells/mm^3)	7.43 ± 0.35^a	7.86 ± 0.02^a	7.90 ± 0.03^a	8.29 ± 0.03^d	8.18 ± 0.01^c	8.08 ± 0.02^b
Leucocrit (%)	1.33 ± 0.57^a	1.66 ± 0.57^a	1.67 ± 0.57^a	2.33 ± 0.57^a	2.00 ± 1.00^a	2.00 ± 1.00^a
Lymphocyte (%)	70.33 ± 0.57^a	72.33 ± 0.57^a	73.00 ± 1.00^a	76.00 ± 1.00^b	74.00 ± 0.58^a	73.00 ± 1.00^a
Monocyte (%)	6.66 ± 0.57^a	10.00 ± 1.00^a	9.33 ± 1.15^a	8.33 ± 0.57^a	9.00 ± 1.00^a	10.00 ± 2.00^a
Neutrophil (%)	6.66 ± 0.57^a	7.33 ± 1.53^a	8.00 ± 1.00^a	6.33 ± 0.57^a	8.00 ± 1.00^a	8.00 ± 1.00^a
Thrombocyte (%)	16.66 ± 0.57^a	9.33 ± 1.52^a	9.66 ± 1.52^a	9.33 ± 0.57^a	9.66 ± 1.15^a	9.00 ± 1.00^a
Phagocytic index (%)	16.66 ± 1.15^a	21.33 ± 1.52^a	21.66 ± 0.57^a	25.66 ± 1.54^b	22.66 ± 1.52^a	22.00 ± 1.00^a
Day 75 (day 14 post-infection with *A. hydrophila*, fed with *C. caudatus* enriched pellets)						
Total erythrocyte (×10^6 cells/mm^3)	1.12 ± 0.02^a	1.09 ± 0.11^a	1.54 ± 0.03^b	1.94 ± 0.04^c	1.75 ± 0.07^{bc}	1.74 ± 0.16^{bc}
Haemoglobin (g/dl)	6.13 ± 0.11^a	5.66 ± 0.11^a	6.93 ± 0.11^b	8.26 ± 0.11^c	8.13 ± 0.23^c	8.06 ± 0.11^c
Haematocrit (%)	25.33 ± 0.57^a	23.00 ± 1.00^a	32.00 ± 1.00^c	35.00 ± 1.00^d	32.00 ± 1.00^c	29.67 ± 0.57^b
Total leucocyte (×10^4 cells/mm^3)	7.43 ± 0.35^a	7.19 ± 0.06^a	8.07 ± 0.03^c	8.02 ± 0.01^c	7.92 ± 0.03^b	7.86 ± 0.05^b
Leucocrit (%)	1.33 ± 0.57^a	1.33 ± 0.57^a	2.00 ± 1.00^a	2.66 ± 0.57^a	2.33 ± 0.57^a	2.00 ± 1.00^a
Lymphocyte (%)	70.33 ± 0.57^a	61.00 ± 1.00^a	75.00 ± 1.00^c	76.67 ± 0.57^d	73.00 ± 1.00^b	72.33 ± 0.57^b
Monocyte (%)	6.66 ± 0.57^a	13.33 ± 0.57^b	9.66 ± 1.15^a	8.00 ± 1.00^a	9.00 ± 1.00^a	9.00 ± 1.00^a
Neutrophil (%)	6.66 ± 0.57^a	11.66 ± 0.57^b	7.66 ± 0.57^a	7.66 ± 0.57^a	8.00 ± 1.00^a	7.66 ± 0.57^a
Thrombocyte (%)	16.66 ± 0.57^a	14.00 ± 1.00^b	7.66 ± 0.57^a	7.67 ± 1.52^a	10.00 ± 3.00^a	11.00 ± 1.00^{ab}
Phagocytic index (%)	16.66 ± 1.15^a	9.33 ± 1.15^a	21.00 ± 1.00^b	27.00 ± 1.00^d	23.66 ± 0.57^c	21.67 ± 1.52^b

$^{a–d}$Different superscripts indicate significant differences ($P < 0.05$); values are means ± SD

Day 0: before *C. caudatus* treatments and *A. hydrophila* infection, day 60: after 60 days treated with *C. caudatus*, before *A. hydrophila* infection; day 75: 14 days after *A. hydrophila* infection

NC = negative control; PC = positive control

Table 7. Water quality in the rearing tanks of *P. hypophthalmus* fed with *C. caudatus* enriched pellets and infected with *A. hydrophila*

Parameters*	Day 0 (pre-treatment)	Day 30 post-treatment	Day 60 post-treatment	Day 75 (day 14 post-infection)	Water quality standards for aquaculture*
Temperature (°C)	26–27	27–28	27–29	28–30	deviation ≤3 °C from natural ambient temperature
pH	6.2–6.5	6.4–6.8	6.6–6.8	6.6–6.9	6–9
DO (ppm)	6.4–5.6	3.7–5.4	3.8–5.2	3.7–4.9	min 3 mg/l
Ammonia (mg/l)	0.02	0.11–0.23	0.78–1.29	2.14–2.20	max 0.2 mg/l

Water quality data were obtained from all experimental units. The Indonesian Class II Water Quality Standards for Aquaculture were based on Government Regulation (PP) No. 22 of 2021

DO = dissolved oxygen

https://doi.org/10.17221/90/2026-CJAS

was sufficient to support the life of *P. hypophthalmus*. The ammonia concentration increased throughout the experiment period from 0.02 mg/l to 2.14–2.20 mg/l.

DISCUSSION

The feeding habit of the control and the treated fish was similar since the addition of *C. caudatus* powder did not negatively affect palatability or reduce the fish's appetite. The fish maintained good feed intake during the treatment period, suggesting that incorporating *C. caudatus* powder into the feed pellets did not substantially affect palatability. Cheng et al. (2015) stated that *C. caudatus*, or "ulam raja", had a unique taste and no negative effects. Meanwhile, Rameli et al. (2021) reported that *C. caudatus* could be consumed cooked or raw. On day 60, data on fish growth reported that there was no variation in body length between the control and treated fish. However, the body weight of the control fish was lighter than those fed with *C. caudatus*-mixed pellets. Therefore, the *C. caudatus*-treated fish were "fatter" than the controls. The consumption improved feed intake, and the plant was used as an appetite enhancer (Bunawan et al. 2014).

On day 61, the fish were injected with a culture of *A. hydrophila* into the dorsal muscle. Furthermore, no clinical signs of bacterial infection were observed, but all infected fish lost appetite and were inactive due to stress. Portz et al. (2006) stated that short-term holding caused stress, suppressed the immune system, decreased growth, reduced swimming performance, declined reproductive capacity, and even caused death. In this study, the fish may be distressed due to short-term handling conducted during the bacterial injection activity. On the 2nd day after infection, all infected fish showed clinical signs of MAS or *A. hydrophila* infection. The fish refused feed, exhibited reduced activity, and developed progressively larger wounds at the injection sites, accompanied by surrounding redness and swelling. Soliman et al. (2022) stated that *A. hydrophila* infection caused clinical signs such as skin haemorrhagic ulceration, cataracts, rotten fins and tails, with gill haemorrhage. During *A. hydrophila* infection, the bacteria produce virulence-associated toxins and enzymes, including aerolysin and proteases, which damage host tissues and contribute to lesion formation, cutaneous ulceration, haemorrhagic dermatitis, and other clinical manifestations. The severity of *A. hydrophila* infection increased under stressful conditions that compromised fish immune responses, including poor water quality, overcrowding, and physical injury (Semwal et al. 2023).

On the 4th day, the clinical signs shown by the positive control and the *C. caudatus*-treated fish were different. The positive control fish that did not consume the *C. caudatus*-mixed pellets showed poor condition. The fish showed signs of severe pathological responses to infection with *A. hydrophila*. The injection sites showed erythematous signs and swelling, and the wounds became necrotic furunculosis lesions. Progressive weakness was also reported, with reduced feeding and death. Wassif and Mohammed (2022) stated that the susceptible organs and tissues of *A. hydrophila* infections included fins, skin, gills, liver, kidney, intestine, and spleen. Several virulence factors were produced, including enzymes, toxins, and adhesins that caused pathogenicity and host tissue alteration (Tomas 2012).

The general condition of the treated fish (T1, T2, and T3) improved. Some fish resumed feeding and active movement, accompanied by progressive wound healing. However, approximately 10–20% of the fish failed to recover and died. On the final day of the experiment, 14 days after infection, almost all fish receiving the *C. caudatus* treatment had recovered, with survival rates ranging from 83.33% to 92%. In contrast, only 40% of the positive control fish survived. The result suggested that dietary supplementation with *C. caudatus* enhanced the fish's immune response against *A. hydrophila* infection.

C. caudatus contains more than 20 antioxidants (Shui et al. 2005; Semwal et al. 2023), with active agents such as phenolic compounds, flavonoids, ascorbic acid, and diphenylpicrylhydrazyl (Rameli et al. 2021; Bunawan et al. 2014). The presence of antioxidant and other active compounds may enable *C. caudatus* to suppress *A. hydrophila* growth (Shui et al. 2005; Semwal et al. 2023). The intake of the compounds through *C. caudatus*-enriched pellet consumption reduced the negative effects of bacterial infection. The ability of the treated fish to face the *A. hydrophila* infection, as well as healing the wound, shows improved immunity. Agusetyaningsih et al. (2022) stated that the intake of antioxidants and other active compounds stimu-

https://doi.org/10.17221/90/2026-CJAS

lated the proliferation of lymphocyte cells in the immune organs.

The differences in clinical signs reported that supplementation with *C. caudatus* significantly enhanced disease resistance in *P. hypophthalmus*. The *C. caudatus* treatment mitigated *A. hydrophila* pathogenicity and reduced the severity of MAS disease symptoms. Additionally, the *C. caudatus*-supplemented fish recovered from MAS disease. There was complete epithelialisation of the wound within 14 days after the infection, and the fish continued to grow. This showed that the treatment stimulated immune function and tissue repair mechanisms.

The histological study on the gill, kidney, and liver of the fish suggested that the supplementation of *C. caudatus* reduced the risk and promoted the repair of the deteriorated tissue due to *A. hydrophila* infection. In the *C. caudatus*-treated fishes (T1, T2 and T3), there were no major abnormalities in the gill structure. The abnormalities were hypertrophy, hyperplasia, epithelial lifting, and curled lamella, categorised as "Stage I" alterations, cured with improved environmental conditions (Poleksic and Mitrovic-Tutundzic 1994). The HAI values of the fishes ranged from 1.8–18.0, corresponding to category 1–20. There was no difference in the tissue of fish provided with different amounts of *C. caudatus*. The results showed that the dosage ranges of *C. caudatus* were sufficient for the fish.

Fish that were not fed *C. caudatus*-enriched pellets (PC) exhibited more severe clinical signs and tissue damage. Gill alterations impaired oxygen uptake and ion regulation, compromising respiratory function. Kidney damage also disrupted ion regulation and contributed to increased ammonia concentrations, leading to internal toxicity (Takvam et al. 2023). Structural damage impaired blood cell production and contributed to anaemia since the kidney is a major haematopoietic organ (Kondera 2019). The occurrence of anaemia was supported by the haematological results presented in Table 6. On day 75, PC fish exhibited the most pronounced reductions in total erythrocyte count, haemoglobin, and haematocrit compared with the values recorded on day 60. These results reported a deterioration in haematological condition and are consistent with the severe kidney and gill damage observed in the histological analysis. The observed anaemia was due to haemolysis associated with enzymes and toxins produced by *A. hydrophila* (Tomas 2012). Impaired erythropoiesis resulted from damage to haematopoietic tissues in the kidney. Fish fed *C. caudatus*-enriched pellets (T1, T2, and T3) maintained higher erythrocyte counts, haemoglobin concentrations, and haematocrit values during the challenge period. This pattern suggests that antioxidant compounds present in *C. caudatus* may have contributed to the protection of erythrocyte membranes against oxidative damage and supported erythropoiesis during *A. hydrophila* infection. Further biochemical and molecular analyses are required to confirm the proposed mechanisms (Witeska et al. 2023).

The supplementation with *C. caudatus* significantly improved feed utilisation in *P. hypophthalmus*. On day 60, the treated fish showed better FCR (1.37–1.48) and FE (68.37–73.12%) compared to the control groups with FCR and FE of 1.83 and 55.63%, respectively. The best result was obtained with T1 (10 g/kg feed), showing FCR and FE of 1.37 and 73.12%, respectively. The improvement in nutrient assimilation may be caused by the presence of the plant's antioxidant compounds (Harsij et al. 2020).

After infection with *A. hydrophila*, the FCR and FE of the *C. caudatus*-treated fish decreased, with FCR and FE at 1.71–1.96 and 50.99–58.67%, respectively. The positive control fish exhibited worse feed conversion since the FCR and FE were 2.04–4.04 and 20.75–49.72%, respectively. This feed conversion was due to infection-induced stress, metabolic disruption (Semwal et al. 2023), and ulcerative septicaemia (Abdul Kari et al. 2022). Data reported that *C. caudatus*-enriched pellets improved baseline nutritional efficiency and protected the fish against the severe decline in feed utilisation. This information offers a practical solution to alleviate productivity losses in commercial aquaculture operations facing disease challenges. The results supported the provision of *C. caudatus*-enriched pellets, especially at the dosage of 10 g/kg feed, in *P. hypophthalmus* culture protocols. The treatment provided an effective, sustainable alternative to antibiotics for preventing *A. hydrophila* outbreaks. This provided additional benefits in maintaining fish welfare and production performance. The rapid wound recovery observed in treated fish suggested that supplementation with *C. caudatus* improved cellular immunity and inflammatory regulation.

C. caudatus powder addition in the fish feed pellets increased the survival of the fish after being infected with *A. hydrophila.* Before the challenge

https://doi.org/10.17221/90/2026-CJAS

test, the fish in all treatments were in good condition, as reflected by the performance, behaviour, and response to feed. Windarti et al. (2026) stated that feeding the fish with *C. caudatus* enriched pellets improved the body weight, FE, and FCR. However, different clinical signs were reported for the infected fish. The positive control fish were the worst, while the fish treated with *C. caudatus* were in better condition. In the *C. caudatus*-treated fish (T1, T2 and T3), the MAS disease clinical signs occurred, but the signs were relatively light. In the PC fish, the ulcer in the injected area started to grow deeper on day 2. The fish refused to eat and became weaker or less active. On day 8 post-infection, the wound worsened, and several fish died. The surviving fish showed positive signs, with recovered wounds and 40% survival. Similar results were obtained by Simarmata et al. (2025), where the administration of *C. caudatus* powder (10 g) in 1 kg feed pellets significantly improved the fish immune response and enabled the fish to resist *A. hydrophila* infection. The ability of the *C. caudatus*-treated fish to face the *A. hydrophila* infection was caused by the improvement of immunity. Yousefi et al. (2021) stated that the use of plant-derived phytochemicals as feed additives offered several benefits, including improved fish growth, enhanced feed efficiency, and increased immune function.

The antioxidant plant polyphenol can interrupt the chain reaction of reactive oxygen species (ROS). This mechanism prevents cellular damage to the fish's leucocytes (white blood cells) and important organs. The immunity enhancement of the *C. caudatus*-treated fish was provided by the haematological analysis data presented in Table 6. The *C. caudatus*-treated fish showed higher total leucocyte count and phagocytic index. These parameters were also higher in the treated fish even before the infection. Therefore, the immune system of the fish had been stimulated by the phytochemical compounds, antioxidant and immunomodulatory agents, flavonoids, and saponins present in *C. caudatus* (Jana et al. 2018). After being infected with *A. hydrophila*, the phagocytic index in the PC fish was sharply decreased. In the *C. caudatus*-treated fish, especially in T1, there was increase in phagocytic index with controlled innate immune response. The lowest *C. caudatus* dosage (T1, 10 g/kg) consistently showed the strongest haematological and immunological response. The higher dosages (T2 and T3) reported smaller improvement. This non-linear dose-dependent pattern may be observed in bioactive compounds derived from saponins and tannins acting as antinutritional or pro-oxidant agents. The obtained data suggested that the optimum dosage of *C. caudatus* in improving the immunity of *P. hypophthalmus* was 10 g/kg feed.

The infected fish were not given medication or chemical antibiotics. In this context, the immune system of the fish was the only factor used to cure the wound. Awad (2025) stated that the natural products significantly improved innate and adaptive immune responses to enhance growth performance and offer antimicrobial properties against various pathogens, including *A. hydrophila*. High survival rate and good health were achieved by fish fed a *C. caudatus* diet, where *C. caudatus* consumption in fish improved the immune system.

The water temperature range was suitable for supporting the life of *P. hypophthalmus* (Table 7) since the tolerable temperature range was 25 °C to 30 °C (Islam et al. 2019). Meanwhile, pH (6.2–6.9) and DO (3.7–5.6) were sufficient for supporting the life of *P. hypophthalmus*. Amalia et al. (2019) showed that the tolerable pH was up to 8.2, while the sufficient DO was 5.37–5.52 mg/l. The highest ammonia content of 2.20 mg/l in water was reported on day 75, around ten times higher than the maximum standard issued by the Indonesian Government. However, this concentration can be tolerated by the fish. Truc et al. (2023) stated that the safe concentrations of LC_{10} and LC_{20}-96 h ammonia on *P. hypophthalmus* were 0.2 and 3.73 mg/l in the controlled media (pH 8 and temperature 28 °C), respectively.

Water volume and quality were maintained daily. Loss of water due to evaporation was replaced to maintain a good volume of clean freshwater. The water was continuously pumped to the aquaponics system in each tank to reduce organic material content in the culture media. The roots of *I. aquatica* planted in the aquaponic system absorbed the organic materials originating from fish metabolic wastes and food remains. Therefore, the quality of water returned to the tank was better. After applying the mechanism, the water quality in each experimental unit was maintained and suitable to support the life of the fish throughout the study. Clinical signs or abnormalities in fish survival and health were not affected by the water condition.

https://doi.org/10.17221/90/2026-CJAS

CONCLUSION

In conclusion, the use of *C. caudatus*-enriched pellets at a dosage of 10 g/kg feed (T1) significantly improved growth performance and immune function in *P. hypophthalmus*. This was evidenced by an increased phagocytic index, improved FE, reduced FCR, fewer clinical signs, protection against gill, kidney, and liver tissue damage, as well as high recovery and survival.

Acknowledgement

The authors also thank the colleagues, students, and team members of the Aquatic Laboratory for their support of this research.

Conflict of interest

The authors declare no conflict of interest.

REFERENCES

Abdella B, Shokrak NM, Abozahra NA, Elshamy YM, Kadira HI, Mohamed RA. Aquaculture and Aeromonas hydrophila: A complex interplay of environmental factors and virulence. Aquacult Int. 2024;32:7671-81.

Abdul Kari Z, Wee W, Mohamad Sukri SA, Che Harun H, Hanif Reduan MF, Irwan Khoo M, Van Doan H, Wen Goh K, Seong Wei L. Role of phytobiotics in relieving the impacts of Aeromonas hydrophila infection on aquatic animals: A mini-review. Front Vet Sci. 2022 Oct 6; 9:1023784.

Agusetyaningsih I, Widiastuti E, Wahyuni HI, Yudiarti T, Murwani R, Sartono TA, Sugiharto S. Effect of encapsulated Cosmos caudatus leaf extract on the physiological conditions, immune competency, and antioxidative status of broilers at high stocking density. Ann Anim Sci. 2022 Apr;22(2):653-62.

Algammal AM, Mohamed MF, Tawfiek BA, Hozzein WN, El Kazzaz WM, Mabrok M. Molecular typing, antibiogram and PCR-RFLP based detection of Aeromonas hydrophila complex isolated from Oreochromis niloticus. Pathogens. 2020 Mar 22;9(3):238.

Amalia R, Hastuti S, Sudaryono A. The effect of earthworm meal (Lumbricus sp.) as an attractant on feed consumption level, feed efficiency and growth of catfish (Pangasius sp.). J Sains Akuakultur Trop. 2019 Mar;3(1):27-35.

Awad E. The role of natural products on the immune status of freshwater fish. Aquacult Int. 2025;33:396.

Bunawan H, Baharum SN, Bunawan SN, Amin NM, Noor NM. Cosmos caudatus Kunth: A traditional medicinal herb. Glob J Pharmacol. 2014;8(3):420-6.

Cheng SH, Barakatun-Nisak MY, Anthony J, Ismail A. Potential medicinal benefits of Cosmos caudatus (Ulam Raja): A scoping review. J Res Med Sci. 2015 Oct;20(10):1000-6.

DKP Kampar. Ikan patin komoditi unggulan yang mengangkat perekonomian Kabupaten Kampar [Pangasius catfish, a leading commodity that raises the economy of Kampar Regency] [Internet]. 2025. Available from: diskan.kamparkab.go.id/artikel-detail/56/ikan-patin-komoditi-unggulan-yang-mengangkat-perekonomian-kabupaten-kampar. Indonesian.

Elsheshtawy A, Yehia N, Elkemary M, Soliman H. Investigation of Nile tilapia summer mortality in Kafr El-Sheikh governorate, Egypt. Genet Aquat Org. 2019;3(1):17-25.

Flores-Lopes F, Thomaz AT. Histopathologic alterations observed in fish gills as a tool in environmental monitoring. Braz J Biol. 2011 Feb;71(1):179-88.

Harsij M, Gholipour Kanani H, Adineh H. Effects of antioxidant supplementation (nano-selenium, vitamin C and E) on growth performance, blood biochemistry, immune status and body composition of rainbow trout (Oncorhynchus mykiss) under sub-lethal ammonia exposure. Aquaculture. 2020;521:734942.

Hasan NA, Haque MM. Dataset of white spot disease affected shrimp farmers disaggregated by the variables of farm site, environment, disease history, operational practices, and saline zones. Data Brief. 2020 Jun 27;31: 105936.

Hasanuddin H. Kode etika penelitian [Research code of ethics]. Banda Aceh: Lembaga Penelitian Universitas Syiah Kuala; 2015. Indonesian.

Islam MA, Uddin MH, Uddin MJ, Shahjahan M. Temperature changes influenced the growth performance and physiological functions of Thai pangas Pangasianodon hypophthalmus. Aquac Rep. 2019 Mar;13:100179.

Jana P, Karmakar S, Roy U, Paul M, Singh AK, Bera KK. Phytobiotics in aquaculture health management: A review. J Entomol Zool Stud. 2018;6(4):1422-9.

Jiang J, Xue M, Liu W, Jiang N, Zhou Y, Liu Y, Li M, Zhong Q, Fan Y. Identification and characterization of pathogenic Aeromonas hydrophila isolated from clinically diseased Chinese rice-field eel, Monopterus albus. Isr J Aquac-Bamidgeh. 2025;77(2):197-210.

Kondera E. Haematopoiesis and haematopoietic organs in fish. Rocz Nauk Pol Tow Zootech. 2019;15(1):9-16.

Korni FMM, El-Nahass ES, Ahmed WMS. An outbreak of motile Aeromonas septicemia in cultured Nile tilapia,

https://doi.org/10.17221/90/2026-CJAS

Oreochromis niloticus, with reference to hematological, biochemical and histopathological alterations. J Fish Pathol. 2017;30(1):11-24.

Nguafack TT, Jang WJ, Hasan MT, Choi YH, Bai SC, Lee EW, Lee BJ, Hur SW, Lee S, Kong IS. Effects of dietary non-viable Bacillus sp. SJ-10, Lactobacillus plantarum, and their combination on growth, humoral and cellular immunity, and streptococcosis resistance in olive flounder (Paralichthys olivaceus). Res Vet Sci. 2020 Aug;131:177-85.

Poleksic V, Mitrovic-Tutundzic V. Fish gills as a monitor of sublethal and chronic effects of pollution. In: Muller R, Lloyd R, editors. Sublethal and chronic effects of pollutants on freshwater fish. Oxford: Fishing News Books; 1994. p. 339-52.

Portz DE, Woodley CM, Cech JJ Jr. Stress-associated impacts of short-term holding on fishes. Rev Fish Biol Fish. 2006 May;16(2):125-70.

Rameli NM, Kader MA, Musa N, Rahmah S, Zainathan S, Ong CH. Cosmos caudatus as a dietary supplement for bagrid catfish, Mystus nemurus. Songklanakarin J Sci Technol. 2021 Mar-Apr;43(2):575-81.

Semwal P, Misra S, Misra A, Kar S, Majhi B, Mishra SK, Srivastava S, Chauhan PS. Endophytic Bacillus strains enhance biomass and bioactive metabolites of Gloriosa superba. Ind Crops Prod. 2023;204:117296.

Shui G, Leong LP, Wong SP. Rapid screening and characterisation of antioxidants of Cosmos caudatus using liquid chromatography coupled with mass spectrometry. J Chromatogr B Analyt Technol Biomed Life Sci. 2005 Nov 15;827(1):127-38.

Simarmata AH, Windarti W, Effendi I. The effectiveness of Cosmos caudatus enriched pellets to improve growth and survival of Pangasianodon hypophthalmus reared in dark saline media. Egypt J Aquat Biol Fish. 2025 May-Jun;29(3):2391-2403.

Siwicki AK, Anderson DP, Antychowicz J. Nonspecific defence mechanisms assay in fish: I. Phagocytic index, adherence and phagocytic ability of neutrophils (NBT test) and myeloperoxidase activity test. In: Siwicki AK, Anderson DP, Waluga J, editors. Fish diseases diagnosis and prevention methods. Olsztyn (Poland): Inland Fisheries Institute; 1993. p. 95

Soliman MK, Nageeb HM, Aboyadak IM, Ali NG. Treatment of MAS caused by Aeromonas sobria in European seabass. Egypt J Aquat Biol Fish. 2022 Sep-Oct;26(5): 535-56.

Takvam M, Wood CM, Kryvi H, Nilsen TO. Role of the kidneys in acid-base regulation and ammonia excretion in freshwater and seawater fish: Implications for nephrocalcinosis. Front Physiol. 2023 Jun 29;14:1226068.

Thornber K, Verner-Jeffreys D, Hinchliffe S, Rahman MM, Bass D, Tyler CR. Evaluating antimicrobial resistance in the global shrimp industry. Rev Aquac. 2020 May;12(2): 966-86.

Tomas JM. The main Aeromonas pathogenic factors. ISRN Microbiol. 2012 Sep 4;2012:256261.

Truc LNT, Luu HTT, Trong NN, Nhi NTH, Phu TQ. Effects of ammonia on the growth, survival and quality of tra catfish (Pangasianodon hypophthalmus). In: Chen L, editor. Current perspectives in agriculture and food science. Vol. 6. BP International; 2023. p. 93-111.

Wassif IM, Mohammed RS. Use of thyme and thymol as immunostimulant agents to control experimental Aeromonas hydrophila infection in Nile tilapia (Oreochromis niloticus). Zagazig Vet J. 2022 Sep;50(3):241-54.

Windarti W, Kurniawan R, Effendi I, Simarmata AH, Efawani E. Growth and survival of Pangasianodon hypophthalmus fed with Cosmos caudatus enriched pellets. IOP Conf Ser Earth Environ Sci. 2026;1581:012009.

Witeska M, Kondera E, Bojarski B. Hematological and hematopoietic analysis in fish toxicology-a review. Animals (Basel). 2023 Aug 14;13(16):2625.

Yousefi M, Ghafarifarsani H, Hoseinifar SH, Rashidian G, Van Doan H. Effects of dietary marjoram, Origanum majorana extract on growth performance, hematological, antioxidant, humoral and mucosal immune responses, and resistance of common carp, Cyprinus carpio against Aeromonas hydrophila. Fish Shellfish Immunol. 2021 Jan; 108:127-33.

Received: July 13, 2026
Accepted: October 13, 2026
Published online: November 26, 2026